

## Short Note

### Visually Detectable Vertebral Malformations of a Bottlenose Dolphin (*Tursiops truncatus*) in the Mississippi Sound

Ashley Millan Ambert,<sup>1</sup> Myстера M. Samuelson,<sup>1</sup>  
Jonathan L. Pitchford,<sup>1,2</sup> and Moby Solangi<sup>1</sup>

<sup>1</sup>*Institute for Marine Mammal Studies, 10801 Dolphin Lane, Gulfport, MS 3250, USA*

*E-mail: msamuelson@imms.org*

<sup>2</sup>*Grand Bay National Estuarine Research Reserve, Moss Point, MS 39562, USA*

Bottlenose dolphins (*Tursiops truncatus*; hereafter “dolphins”) are considered sentinels of the marine environment due to their relatively long life span and their status as top-level predators in the marine food chain (Wells et al., 2004). Vertebral malformations are not unknown in free-ranging dolphins (Wilson et al., 1997; Berghan & Visser, 2000; Haskins & Robinson, 2007; Bearzi et al., 2009; DeLynn et al., 2011). These vertebral deformities can become outwardly apparent in the form of scoliosis (a lateral curvature of the spine), kyphosis (i.e., increased convexity in the curvature of the spinal column as viewed from the side), and/or lordosis (anterior concavity in the curvature of the vertebrae) (Wise et al., 1997).

Scoliosis has been divided into two distinct categories: (1) idiopathic scoliosis (IS) and (2) congenital scoliosis (CS), each of which is defined based upon the probable cause. IS develops in both young and adult dolphins and has no single known cause. It is hypothesized that IS is a result of infectious disease (such as spondylo-osteomyelitis [Kompanje, 1995] and diskospondylitis [Alexander et al., 1989]); trauma (Kompanje & Garcia Hartmann, 2001; DeLynn et al., 2011), including boat strikes (Robinson, 2014); and intraspecific aggression (Nutman & Kirk, 1988; Watson et al., 2004; DeLynn et al., 2011). Alternately, CS occurs as a result of anomalous embryonic development (DeLynn et al., 2011). In other species, such as humans and mice, chromosomal abnormalities and allelic mutations in genes associated with developmental pathways have been observed (Giampietro et al., 2003; Farley, 2010; Giampietro, 2012). Also, in humans, CS has been demonstrated to be likely caused by environmental factors such as exposure to teratogens present in the ecosystem (Giampietro et al., 2003; Giampietro, 2012).

Cases of vertebral malformations in cetaceans have been documented in multiple geographic regions, including northeastern Scotland (Wilson et al., 1997; Haskins & Robinson, 2007), New Zealand, and Iceland (Berghan & Visser, 2000). The dolphin population of the Moray Firth in Scotland has been documented as having a high prevalence of vertebral deformities (Haskins & Robinson, 2007). A 4-y study by Wilson et al. (1997) documented physical malformations that included observations of “humpbacked” animals, the presence of “lumps” protruding from the lateral sides of several individuals, and bent dorsal fins in 6% of the Moray Firth dolphin population. Within this 6% that presented with physical malformations, the prevalence of conformational vertebral deformities was calculated at 4.9% (Wilson et al., 1997).

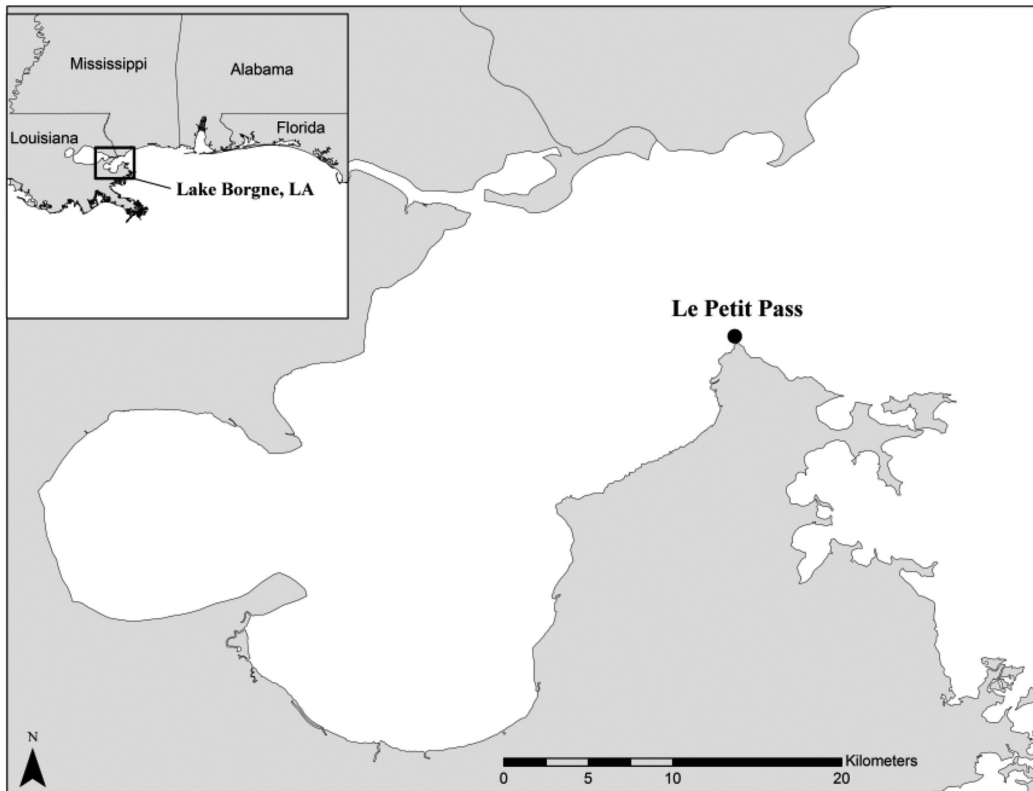
An adult dolphin exhibiting lordosis and kyphosis was sighted on 25 September 2015 during a photo-identification (photo-ID) survey in the northern Gulf of Mexico estuary, Lake Borgne, Louisiana. Lake Borgne designates the western boundary of the Mississippi Sound (MSS), delineated by lines that connect Malheureux Point with Le Petit Pass (Eleuterius, 1978a; Figure 1). This is the first known report of a dolphin with outwardly apparent vertebral deformities in the MSS. The data presented provide a basis for comparison with other cases from the literature. The Institute for Marine Mammal Studies (IMMS) in Gulfport, Mississippi, has conducted monthly boat-based photo-ID surveys in the MSS since 2011 (weather permitting). The survey platform was a 6.4-m vessel powered by a single 150-hp Evinrude E-Tech outboard engine and traveling at a maximum speed of 40 km/h while on survey. Boat speed was reduced to match the pace of a dolphin group during a sighting, which lasted no longer than 30 min (as

per Permit GA LOC #18185). A minimum of four observers searched for dolphins and recorded the sightings. Group size, composition, and behavioral states were documented in addition to weather and environmental conditions such as sea state, depth, and water quality (temperature, pH, salinity, and dissolved oxygen). Group locations were recorded using a handheld Garmin GPSmap76 global positioning system (GPS), and photographs of individual dorsal fins in each group were taken using a Canon EOS 50D or 60D digital camera with a Canon 400-mm zoom lens.

The MSS has a surface area of  $\sim 2,100$  km<sup>2</sup> (Eleuterius, 1978a, 1978b) and extends from Lake Borgne, Louisiana, to Mobile Bay, Alabama. This area is home to one of the largest estuarine populations of bottlenose dolphins in the United States (Waring et al., 2014). Seasonal population size estimates range from 738 (CV = 31.3%) to 3,236 (CV = 21.6%) (Pitchford et al., 2016). The surface area of Lake Borgne is 730 km<sup>2</sup>, with an average depth of 3 m and an average salinity of 7 ppt (U.S. Environmental Protection Agency [USEPA], 1999).

All sighting data were entered into *FinBase*, Version 2.0, and sighting location coordinates were imported into *ESRI® ArcMap™*, Version 9.3. Using *Darwin*, Version 2.22, each individual fin encountered during the survey was compared against the IMMS database to determine the individual's previous sighting history. Once all individuals were compared against the IMMS database ( $n = 2,886$  at the time of the sighting), the apparent prevalence (AP) of vertebral deformities in the dolphin population of the MSS was estimated by adapting calculation methods used by Greiner & Gardner (2000).

On 25 September 2015, during a dolphin survey of Lake Borgne, a dolphin with obvious vertebral malformations was observed in Le Petit Pass, southwest of Le Petit Island in St. Bernard Parish, Louisiana (30° 5' 3.984" N, -89° 29' 8.879" W). The individual was seen in association with an estimated 12 adult dolphins that were feeding behind a shrimp trawler. Feeding behavior was evidenced from fish seen in mouths, the presence of fish, and birds feeding alongside the dolphins as defined in Cook et al. (2004). *Trawler foraging*




**Figure 1.** Le Petit Pass, the sighting area of a bottlenose dolphin (*Tursiops truncatus*) with visually detectable lordosis and kyphosis

was defined by diving behavior in the area surrounding the trawler's net (Chilvers & Corkeron, 2001).

The individual encountered was an adult dolphin (adult age class categorized as an individual approximately 2.5 to 3 m in length; Bearzi et al., 1997) of unknown sex. During the encounter, researchers were able to visually assess the majority of the dorsal portion of the body, spanning from the melon to the caudal peduncle near the flukes. Body areas not viewed included the ventral surface (including pectoral fins) and both the ventral and dorsal areas of the flukes.

To confirm the condition, a veterinarian was consulted during photographic analysis. The animal was observed to have lordosis at the thoracic region (Figure 2a) and kyphosis in the dorsocaudal region (Figure 2b). A slight kyphotic hump was also visible on the right lateral side of the dolphin, directly caudal to the dorsal fin (Figure 2c).

The IMMS database contains a total of 2,886 dolphins individually identified since 2011. The dolphin observed was not present in the database, which includes photo-ID data spanning a total of 4 y, and was consequently added. The observation of the malformed dolphin marked the first case of



**Figure 2.** Pictures of an adult dolphin observed on 25 September 2015 in the Mississippi Sound (MSS) with lordosis (designated by arrow in “a”) and kyphosis (designated by arrow in “b”). A slight kyphotic hump was present on the right side of the dolphin, directly caudal to the dorsal fin (designated by arrow in “c”).

an individual with outwardly apparent vertebral malformations in our records and the first known dolphin with a spinal deformity in the MSS. The AP of vertebral deformities within this population was estimated to be 0.037%. It should be noted, however, that the actual prevalence of vertebral deformities within this population may be much higher in actuality as some malformations may not be outwardly apparent.

Observations of dolphins with vertebral deformities resulting from trauma are usually accompanied by skin lesions, wounds, or scars thought to be the result of injury (Wilson et al., 1997; Patterson et al., 1998; Berghan & Visser, 2000; Bearzi et al., 2009; Robinson, 2014). Entanglements with fishing gear and boat collisions often leave visually distinct scarring on cetaceans. Characteristics of past entanglements often include linear scars in the form of lacerations caused by monofilament line and nets, and abrasions resulting from gear rubbing on the animal's skin (Wells et al., 1998, 2008). Injuries caused by boat strikes are characterized by parallel and evenly spaced wounds or scarring and are typically observed on the dorsal fin and/or on the dorsocaudal region (Wells & Scott, 1997). In the case of this observed dolphin, visual assessment indicated a lack of scarring on the body, suggesting it is unlikely that this malformation was a result of traumatic injury.

Despite the vertebral deformity, the dolphin's motor function appeared to be relatively unaffected as evidenced by normal feeding behavior, as well as by the location of the malformation itself. The swimming motion of cetaceans is facilitated by the dorsoventral undulation of the caudal region in conjunction with the movement of the flukes (Fish & Hui, 1991; Long et al., 1997; Pabst, 2000). However, the deformities observed on the dolphin appeared to be present mainly in the mid-thoracic region of the body. Therefore, it is likely that the malformation may not have had much impact on the individual's locomotion. More data are needed to gain a comprehensive understanding of the effects of vertebral malformations on the swimming motion of cetaceans. Berghan & Visser (2001) described the swimming behavior of a scoliotic Hector's dolphin (*Cephalorhynchus hectori*) calf observed in New Zealand as having a pulse-like motion (moving forward in bursts); however, it appeared to travel at the same speed as the adult by which it was accompanied. Moreover, Kranenbarg et al. (2005) demonstrated that lordotic vertebrae in European sea bass (*Dicentrarchus labrax* L.) became acclimated to the increase of lateral muscle activity and bending movement by having greater bone deposition than normal vertebrae. It should be noted, however, that some causes of vertebral malformations, such

as trauma, may also cause secondary ailments, such as infection (Bertulli et al., 2015), making it difficult to ascertain the role of the abnormality in assessing the animals' longevity in some cases.

The observed dolphin was an adult (~2.5 to 3 m long), which is not uncommon for an animal with this type of deformity (Berghan & Visser, 2000; Watson et al., 2004; Haskins & Robinson, 2007). Case studies of dolphins with vertebral malformations have indicated that the condition may not pose a threat to longevity and reproductive fitness. Wells et al. (2008) described a male dolphin with scoliosis in its caudal peduncle that lived for over 25 y. Similarly, DeLynn et al. (2011) reported a female resident dolphin in Sarasota Bay, Florida, that lived for 18 y and successfully gave birth to two calves despite showing characteristics of CS malformation. Long-term studies of the Sarasota dolphin population have determined that females may tend to have higher life expectancies than males (female mean age = 17.5 y, male mean age = 12.3 y; Wells et al., 1987), with the oldest dolphin aged over 50 y (Hohn et al., 1989; Wells & Scott, 1999).

Home ranges of cetaceans have been documented to extend beyond the areas studied in mark-recapture research (Durban et al., 2005; Urian et al., 2015). While it is possible that others with similar outwardly apparent vertebral deformities have frequented the region undetected, this encounter was the first known account of a dolphin presenting characteristics of vertebral malformation consisting of lordosis and kyphosis in the MSS.

This case provides a basis for comparison with other regions where vertebral malformations have been frequently documented (Ross & Wilson, 1996; Wilson et al., 1997; Haskins & Robinson, 2007; Bertulli et al., 2015). Prevalence of conformational deformities in the dolphin population of the Moray Firth has been reported at 4.9% (Wilson et al., 1997). In comparison, the AP of vertebral malformation for the population of the MSS was calculated at 0.037%. Taking into consideration that monthly surveys have been occurring in this area since 2011, the AP provides an indication of the rarity of this condition in the MSS. Continued photo-ID study of dolphins in the MSS is necessary to assess the status of the dolphin population. While opportunities for the collection of data in free-ranging animals are limited, future research would benefit from capture-release health assessments of dolphins in the area. Radiographic evaluation in conjunction with histopathological analysis of dolphins with vertebral malformations would prove invaluable in identifying the etiology of the condition in the population.

### Acknowledgments

We would like to thank the Marine Mammal Research Department at the Institute for Marine Mammal Studies (IMMS), including Jennifer Sentinella, Quincy Goeke, Rachel Amos, Trevor Jensen, Victoria Howard, and the interns who assisted with data collection. We extend special thanks to veterinarian Debra Moore for offering helpful counsel during the assessment of the malformations observed, and Eric Pulis for providing constructive comments on previous drafts of this manuscript. All field research was conducted under NOAA, National Marine Fisheries Service Permit GA LOC #18185. We would also like to thank the IMMS for funding these research efforts.

### Literature Cited

- Alexander, J. W., Solangi, M. A., & Riegel L. S. (1989). Vertebral osteomyelitis and suspected diskospondylitis in an Atlantic bottlenose dolphin (*Tursiops truncatus*). *Journal of Wildlife Diseases*, 25(1), 118-121. <https://doi.org/10.7589/0090-3558-25.1.118>
- Bearzi, G., Notarbartolo di Sciara, G., & Politi, E. (1997). Social ecology of bottlenose dolphins in the Kvarnerić (northern Adriatic Sea). *Marine Mammal Science*, 13(4), 650-668. <https://doi.org/10.1111/j.1748-7692.1997.tb00089.x>
- Bearzi, M., Rapoport, S., Chau, J., Saylan, C., Area, S., Canyon, M., . . . Collection, D. (2009). Skin lesions and physical deformities of coastal and offshore common bottlenose dolphins (*Tursiops truncatus*) in Santa Monica Bay and adjacent areas, California. *Ambio*, 38(2), 66-71. <https://doi.org/10.1579/0044-7447-38.2.66>
- Berghan, J., & Visser, I. N. (2000). Vertebral column malformations in New Zealand delphinids with a review of cases world wide. *Aquatic Mammals*, 26(1), 17-25.
- Bertulli, C. G., Galatius, A., Kinze, C. C., Rasmussen, M. H., Deaville, R., Jepson, P., . . . Watson, A. (2015). Vertebral column deformities in white-beaked dolphins from the eastern North Atlantic. *Diseases of Aquatic Organisms*, 116(1), 59-67. <https://doi.org/10.3354/dao102904>
- Chilvers, B. L., & Corkeron, P. J. (2001). Trawling and bottlenose dolphins' social structure. *Proceedings of the Royal Society of London, Series B: Biological Sciences*, 268(1479), 1901-1905. <https://doi.org/10.1098/rspb.2001.1732>
- Cook, M. L. H., Sayigh, L. S., Blum, J. E., & Wells, R. S. (2004). Signature-whistle production in undisturbed free-ranging bottlenose dolphins (*Tursiops truncatus*). *Proceedings of the Royal Society of London, Series B: Biological Sciences*, 271(1543), 1043-1049. <https://doi.org/10.1098/rspb.2003.2610>
- DeLynn, R., Lovewell, G., Wells, R. S., & Early, G. (2011). Congenital scoliosis of a bottlenose dolphin. *Journal of Wildlife Diseases*, 47(4), 979-983. <https://doi.org/10.7589/0090-3558-47.4.979>
- Durban, J. W., Elston, D. A., Ellifrit, D. K., Dickson, E., Hammond, P. S., & Thompson, P. M. (2005). Multisite mark-recapture for cetaceans: Population estimates with Bayesian Model averaging. *Marine Mammal Science*, 21(1), 80-92. <https://doi.org/10.1111/j.1748-7692.2005.tb01209.x>
- Eleuterius, C. K. (1978a). Geographical definition of Mississippi Sound. *Gulf Research Reports*, 6(2), 179-181. <https://doi.org/10.18785/gr.0602.10>
- Eleuterius, C. K. (1978b). Classification of Mississippi Sound as to estuary hydrological type. *Gulf Research Reports*, 6(2), 185-187. <https://doi.org/10.18785/gr.0602.12>
- Farley, F. A. (2010). Etiology of congenital scoliosis. *Seminars in Spine Surgery*, 22(3), 110-112. <https://doi.org/10.1053/j.semss.2010.03.001>
- Fish, F. E., & Hui, C. A. (1991). Dolphin swimming: A review. *Mammal Review*, 21(4), 181-195. <https://doi.org/10.1111/j.1365-2907.1991.tb00292.x>
- Giampietro, P. F. (2012). Genetic aspects of congenital and idiopathic scoliosis. *Scientifica*, 2012(Cvm), 152365. <https://doi.org/10.6064/2012/152365>
- Giampietro, P. F., Blank, R. D., Raggio, C. L., Merchant, S., Jacobsen, F. S., Faciszewski, T., . . . Schwalter, D. B. (2003). Congenital and idiopathic scoliosis: Clinical and genetic aspects. *Clinical Medicine & Research*, 1(2), 125-136. Retrieved from [www.pubmedcentral.nih.gov/articlerender.fcgi?artid=1069035&tool=pmcentrez&rendertype=abstract](http://www.pubmedcentral.nih.gov/articlerender.fcgi?artid=1069035&tool=pmcentrez&rendertype=abstract). <https://doi.org/10.3121/cm.1.2.125>
- Greiner, M., & Gardner, I. A. (2000). Epidemiologic issues in the validation of veterinary diagnostic tests. *Preventive Veterinary Medicine*, 45(1-2), 3-22. [https://doi.org/10.1016/S0167-5877\(00\)00114-8](https://doi.org/10.1016/S0167-5877(00)00114-8)
- Haskins, G. N., & Robinson, K. P. (2007). Visually-detectable attributes of spinal malformations in free-ranging bottlenose dolphin calves in northeast Scotland. *Journal of Wildlife Diseases*, 20, 248-250.
- Hohn, A. A., Scott, M. D., Wells, R. S., Sweeney, J. C., & Irvine, A. B. (1989). Growth layers in teeth from known-age, free-ranging bottlenose dolphins. *Marine Mammal Science*, 5(4), 315-342. <https://doi.org/10.1111/j.1748-7692.1989.tb00346.x>
- Kompanje, E. J. O. (1995). Differences between spondylo-osteomyelitis and spondylosis deformans in small odontocetes based on museum material. *Aquatic Mammals*, 21(3), 199-203. Retrieved from [www.aquaticmammals-journal.org/share/AquaticMammalsIssueArchives/1995/AquaticMammals\\_21-03/21-03\\_Kompanje.pdf](http://www.aquaticmammals-journal.org/share/AquaticMammalsIssueArchives/1995/AquaticMammals_21-03/21-03_Kompanje.pdf)
- Kompanje, E. J. O., & García Hartmann, M. (2001). Intraspongious disc dermiation (Schmorl's node in *Phocoena phocoena* and *Lagenorhynchus albirostris* (Mammalia: Cetacea, Odontoceti)). *Deinsea*, 8, 135-141.
- Kranenbarg, S., Waarsing, J. H., Muller, M., Weinans, H., & Van Leeuwen, J. L. (2005). Lordotic vertebrae in sea bass (*Dicentrarchus labrax* L.) are adapted to increased loads. *Journal of Biomechanics*, 38(6), 1239-1246. <https://doi.org/10.1016/j.jbiomech.2004.06.011>

- Long, J. H., Pabst, D. A., Shepherd, W. R., & McLellan, W. A. (1997). Locomotor design of dolphin vertebral columns: Bending mechanics and morphology of *Delphinus delphis*. *Journal of Experimental Biology*, 200(1), 65-81.
- Nutman, A. W., & Kirk, E. J. (1988). Abnormalities in the axial skeleton of a Risso's dolphin, *Grampus griseus*. *New Zealand Veterinary Journal*, 36(2), 91-92. <https://doi.org/10.1080/00480169.1988.35490>
- Pabst, D. A. (2000). To bend a dolphin: Convergence of force transmission designs in cetaceans and scombrid fishes. *American Zoologist*, 40, 146-155. [https://doi.org/10.1668/0003-1569\(2000\)040\[0146:TBADCO\]2.0.CO;2](https://doi.org/10.1668/0003-1569(2000)040[0146:TBADCO]2.0.CO;2)
- Patterson, I. A., Reid, R. J., Wilson, B., Grellier, K., Ross, H. M., & Thompson, P. M. (1998). Evidence for infanticide in bottlenose dolphins: An explanation for violent interactions with harbour porpoises? *Proceedings of the Royal Society of London, Series B: Biological Sciences*, 265(1402), 1167-1170. <https://doi.org/10.1098/rspb.1998.0414>
- Pitchford, J. L., Pulis, E. E., Evans, K., Shelley, J. K., Serafin, B. J., & Solangi, M. (2016). Seasonal density estimates of *Tursiops truncatus* (bottlenose dolphin) in the Mississippi Sound from 2011 to 2013. *Southeastern Naturalist*, 15(2), 188-206. <https://doi.org/10.1656/058.015.0201>
- Robinson, K. P. (2014). Agonistic intraspecific behavior in free-ranging bottlenose dolphins: Calf-directed aggression and infanticidal tendencies by adult males. *Marine Mammal Science*, 30(1), 381-388. <https://doi.org/10.1111/mms.12023>
- Ross, H. M., & Wilson, B. (1996). Violent interactions between bottlenose dolphins and harbour porpoises. *Proceedings of the Royal Society of London, Series B: Biological Sciences*, 263(1368), 283-286. <https://doi.org/10.1098/rspb.1996.0043>
- U.S. Environmental Protection Agency (USEPA). (1999). *Ecological condition of estuaries in the Gulf of Mexico* (EPA 620-R-98-004). Gulf Breeze, FL: USEPA, Office of Research and Development, National Health and Environmental Effects Research Laboratory, Gulf Ecology Division.
- Urian, K., Gorgone, A., Read, A., Balmer, B., Wells, R. S., Berggren, P., . . . Hammond, P. S. (2015). Recommendations for photo-identification methods used in capture-recapture models with cetaceans. *Marine Mammal Science*, 31(1), 298-321. <https://doi.org/10.1111/mms.12141>
- Waring, G. T., Josephson, E., Maze-Foley, K., Rosel, P. E., Byrd, B., Cole, T. V. N., . . . Wenzel, F. W. (2014). *U.S. Atlantic and Gulf of Mexico marine mammal stock assessments – 2014* (NOAA Technical Memorandum NMFS-NE-228). Silver Spring, MD: National Oceanic and Atmospheric Administration.
- Watson, A., Bahr, R. J., & Alexander, J. W. (2004). Thoracolumbar kyphoscoliosis and compression fracture of a thoracic vertebra in a captive bottlenose dolphin (*Tursiops truncatus*). *Aquatic Mammals*, 30(2), 275-278. <https://doi.org/10.1578/AM.30.2.2004.275>
- Wells, R. S., & Scott, M. D. (1997). Seasonal incidence of boat strikes on bottlenose dolphins near Sarasota, Florida. *Marine Mammal Science*, 13(3), 475-480. <https://doi.org/10.1111/j.1748-7692.1997.tb00654.x>
- Wells, R. S., & Scott, M. D. (1999). Bottlenose dolphin (*Tursiops truncatus*) (Montagu, 1821). In S. H. Ridgway & R. Harrison (Eds.), *Handbook of marine mammals: The second book of dolphins and porpoises* (Vol. 6, pp. 137-182). San Diego: Academic Press.
- Wells, R. S., Hofmann, S., & Moors, T. L. (1998). *Tursiops truncatus*. *Fishery Bulletin*, 96, 647-650.
- Wells, R. S., Scott, M. D., & Irvine, A. B. (1987). The social structure of free-ranging bottlenose dolphins. In H. H. Genoways (Ed.), *Current mammalogy* (pp. 247-305). Boston: Springer. [https://doi.org/10.1007/978-1-4757-9909-5\\_7](https://doi.org/10.1007/978-1-4757-9909-5_7)
- Wells, R. S., Allen, J. B., Hofmann, S., Bassos-Hull, K., Fauquier, D. A., Barros, N. B., . . . Scott, M. D. (2008). Consequences of injuries on survival and reproduction of common bottlenose dolphins (*Tursiops truncatus*) along the west coast of Florida. *Marine Mammal Science*, 24(4), 774-794. <https://doi.org/10.1111/j.1748-7692.2008.00212.x>
- Wells, R. S., Rhinehart, H. L., Hansen, L. J., Sweeney, J. C., Townsend, F. I., Stone, R., . . . Rowles, T. K. (2004). Bottlenose dolphins as marine ecosystem sentinels: Developing a health monitoring system. *EcoHealth*, 1, 246-254. <https://doi.org/10.1007/s10393-004-0094-6>
- Wilson, B., Thompson, P. M., & Hammond, P. S. (1997). Skin lesions and physical deformities in bottlenose dolphins in the Moray Firth: Population prevalence and age-sex differences. *Ambio*, 26(4), 243-247.
- Wise, L. D., Beck, S. L., Beltrame, D., Beyer, B. K., Chahoud, I., Clark, R. L., . . . York, R. G. (1997). Terminology of developmental abnormalities in common laboratory mammals (Version 1). *Congenital Anomalies*, 37 [Online]. <https://doi.org/10.1111/j.1741-4520.1997.tb00975.x>