







**Prevalence of Skin Lesions and Injuries in
Australian Humpback Dolphins (*Sousa sahulensis*) and
Indo-Pacific Bottlenose Dolphins (*Tursiops aduncus*)
in Moreton Bay, Queensland**

Supplementary Tables


Elizabeth R. Hawkins, Mia Gustavsson, Lara Pogson-Manning,
Heather Pheloung, and Christian Jaehnichen

*Dolphin Research Australia, PO Box 1960, Byron Bay, New South Wales, 2481, Australia
E-mail: liz@dolphinresearchaustralia.org*

Table S1. Primary and secondary skin lesion categories of nontraumatic and traumatic classification for Australian humpback dolphins (*Sousa sahulensis*) and Indo-Pacific bottlenose dolphins (*Tursiops aduncus*) in Moreton Bay, Queensland

Primary lesion category	Description	References
Nontraumatic		
<i>Annular lesion</i>		
	Ring-like lesion with light grey centre with concentric rings	Van Bresseem et al., 2015; Hupman et al., 2017
<i>Dark lesion</i>		
	<i>Black spots</i> – Hyperpigmentation; small black dots. Can be slightly raised.	Van Bresseem et al., 2008; Toms et al., 2020
	<i>Dark centre</i> – Hyperpigmentation, dark grey colour in centre, lighter outer fringe, and irregular in shape	Chabanne et al., 2012; Hupman et al., 2017
	<i>Other</i> – Dark in colour, irregular shape, no light fringe, and doesn't fit other definitions	Chabanne et al., 2012
	<i>Tattoo-like skin disease</i> – Stippled lesion that can be grey or black in colour. Can have dark border that fades to a lighter colour as it regresses. Shape can be irregular, round, or ring-like.	Geraci et al., 1979; Van Bresseem et al., 2003, 2015; Chabanne et al., 2012; Powell et al., 2018
		

Orange spots/film



Non-raised orange or rusty coloured dots or blotches. Film on surface of skin.

Maldini et al., 2010; Yang et al., 2013; Van Bresseem et al., 2015

Pale dermatitis



Irregular, slightly raised sores that are pale in colour. Ulcerated or velvety appearance.

Van Bresseem et al., 2015

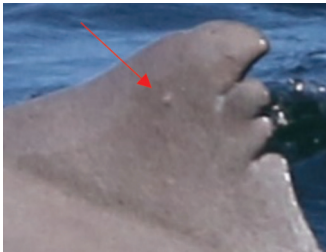
Pale lesion



Lighter than surrounding skin. Can be circular or amorphous and irregular in shape. Smooth and even with the surface of the skin.

Wilson et al., 1997; Yang et al., 2013

Nodular



Nodular, raised bumps, rounded at top. Can be normal skin colour, orange, reddish, or ulcerated lumps on skin.

Van Bresseem et al., 2009, 2015; Chabanne et al., 2012; Yang et al., 2013

Targetoid



Dark fringed – Light centre with dark ring fringe


Wilson et al., 1997; Chabanne et al., 2012



Light fringed – Dark centre with light ring fringe

Traumatic


Abrasions/excoriations



Rake marks – Multiple parallel lines or scrapes from conspecific bites; single tear/scrape.

Scott et al., 2005; Chabanne et al., 2012; Luksenburg, 2014

Anthropogenic




Entanglement in debris or fishing gear – Clean cuts with indentations on opposing sides of the dorsal fin, tail fluke, peduncle, or pectoral fin. Dorsal fins with linear marks that are linked to mutilations or injuries, including collapsed or missing dorsal fins, tail flukes, or pectoral fins.

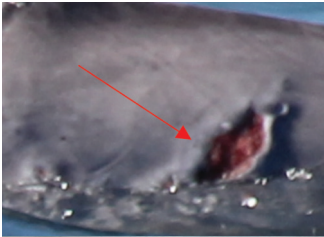Wells et al., 1990; Wells & Scott, 1997; Baird & Gorgone, 2005; Kiszka et al., 2008; Chabanne et al., 2012; Luksenburg, 2014



Boat/propeller strike – Sequence of parallel clean cuts or scarring with a greater distance between cuts than rake marks. Clean v-shaped indentation on the peduncle, flank, or dorsal fin from vessel propeller or hull.



Bite wounds



Fresh bite wounds – Crescent-shaped wounds with evident crescent-shaped rake marks, often with tears and scrapes associated with shark teeth. Space between scrapes are larger than those caused by conspecifics. Bite wound is fresh, and the epidermal layer is broken.

Corkeron et al., 1987; Heithaus, 2001; Chabanne et al., 2012; Smith et al., 2017



Healed bite wounds – Crescent-shaped scarring with evidence of rake marks caused by a shark bite. Epidermal layer is healed.

Indentation



Depression along the caudal peduncle or dorsal fin that can be irregular or cleanly shaped

Luksenburg, 2014; Félix et al., 2018


Laceration/incision



Clean cut or gash across the epidermal layer

Chabanne et al., 2012

Missing tip



Tip of a body segment (dorsal fin, tail fluke, or rostrum) has been cut off or deformed

Luksenburg, 2014; Félix et al., 2018

Open wound



Fresh, open wound from an unknown source

Unknown scarring



Raised – Elevated, healed scarring from an unknown source

Chabanne et al., 2012; Hupman et al., 2017



Depressed – Scars that appear sunken from unknown source



Other – Unclassified scarring from an unknown source

Literature Cited in Table S1

- Baird, R. W., & Gorgone, A. M. (2005). False killer whale dorsal fin disfigurements as a possible indicator of long-line fishery interactions in Hawaiian waters. *Pacific Science*, 59(4), 593-601. <https://doi.org/10.1353/psc.2005.0042>
- Chabanne, D., Harrison, L., Holyoake, C., Finn, H., Stephens, N., & Bejder, L. (2012). *Swan Canning Riverpark dolphin population ecology & health investigations* (Report). Murdoch University Cetacean Research Unit, Perth, Western Australia. <https://researchrepository.murdoch.edu.au/id/eprint/38588>
- Corkeron, P. J., Morris, R. J., & Bryden, M. M. (1987). Interactions between bottlenose dolphins and sharks in Moreton Bay, Queensland. *Aquatic Mammals*, 13(3), 109-113.
- Félix, F., Centeno, R., Romero, J., Zavala, M., & Vásconez, Ó. (2018). Prevalence of scars of anthropogenic origin in coastal bottlenose dolphin in Ecuador. *Journal of the Marine Biological Association of the United Kingdom*, 98(5), 1177-1186. <https://doi.org/10.1017/S0025315417000686>
- Geraci, J., Hicks, B., & St. Aubin, D. (1979). Dolphin pox: A skin disease of cetaceans. *Canadian Journal of Comparative Medicine*, 43(4), 399-404.
- Heithaus, M. R. (2001). Shark attacks on bottlenose dolphins (*Tursiops aduncus*) in Shark Bay, Western Australia: Attack rate, bite scar frequencies, and attack seasonality. *Marine Mammal Science*, 17(3), 526-539. <https://doi.org/10.1111/j.1748-7692.2001.tb01002.x>
- Hupman, K. E., Pawley, M. D., Lea, C., Grimes, C., Voswinkel, S., Roe, W. D., & Stockin, K. A. (2017). Viability of photo-identification as a tool to examine the prevalence of lesions on free-ranging common dolphins (*Delphinus* sp.). *Aquatic Mammals*, 43(3), 264-278. <https://doi.org/10.1578/AM.43.3.2017.264>
- Kiszka, J., Pelourdeau, D., & Ridoux, V. (2008). Body scars and dorsal fin disfigurements as indicators interaction between small cetaceans and fisheries around the Mozambique Channel island of Mayotte. *Western Indian Ocean Journal of Marine Science*, 7(2), 185-193. <https://doi.org/10.4314/wiojms.v7i2.48276>
- Luksenburg, J. A. (2014). Prevalence of external injuries in small cetaceans in Aruban waters, Southern Caribbean. *PLOS ONE*, 9(2), e88988. <https://doi.org/10.1371/journal.pone.0088988>
- Maldini, D., Riggan, J., Cecchetti, A., & Cotter, M. P. (2010). Prevalence of epidermal conditions in California coastal bottlenose dolphins (*Tursiops truncatus*) in Monterey Bay. *Ambio*, 39, 455-462. <https://doi.org/10.1007/s13280-010-0066-8>
- Powell, S. N., Wallen, M. M., Bansal, S., & Mann, J. (2018). Epidemiological investigation of tattoo-like skin lesions among bottlenose dolphins in Shark Bay, Australia. *Science of the Total Environment*, 630, 774-780. <https://doi.org/10.1016/j.scitotenv.2018.02.202>
- Scott, E. M., Mann, J., Watson-Capps, J. J., Sargeant, B. L., & Connor, R. C. (2005). Aggression in bottlenose dolphins: Evidence for sexual coercion, male-male competition, and female tolerance through analysis of tooth-rake marks and behaviour. *Behaviour*, 142(1), 21-44. <https://doi.org/10.1163/1568539053627712>
- Smith, F., Allen, S. J., Bejder, L., & Brown, A. M. (2018). Shark bite injuries on three inshore dolphin species in tropical northwestern Australia. *Marine Mammal Science*, 34(1), 87-99. <https://doi.org/10.1111/mms.12435>
- Toms, C. N., Stone, T., & Och-Adams, T. (2020). Visual-only assessments of skin lesions on free-ranging common bottlenose dolphins (*Tursiops truncatus*): Reliability and utility of quantitative tools. *Marine Mammal Science*, 36(3), 744-773. <https://doi.org/10.1111/mms.12670>
- Van Bresseem, M-F., Gaspar, R., & Aznar, F. J. (2003). Epidemiology of tattoo skin disease in bottlenose dolphins *Tursiops truncatus* from the Sado estuary, Portugal. *Diseases of Aquatic Organisms*, 56, 171-179. <https://doi.org/10.3354/dao056171>
- Van Bresseem, M-F., Santos, M. C. O., & Oshima, J. E. F. (2009). Skin diseases in Guiana dolphins (*Sotalia guianensis*) from the Paranaguá estuary, Brazil: A possible indicator of a compromised marine environment. *Marine Environmental Research*, 67(2), 63-68. <https://doi.org/10.1016/j.marenvres.2008.11.002>
- Van Bresseem, M-F., Flach, L., Reyes, J. C., Echegaray, M., Santos, M., Vididi, F., Félix, F., Lodi, L., & Van Waerebeek, K. (2015). Epidemiological characteristics of skin disorders in cetaceans from South American waters. *Latin American Journal of Aquatic Mammals*, 10(1), 20-32. <https://doi.org/10.5597/lajam190>
- Van Bresseem, M-F., Van Waerebeek, K., Flach, L., Reyes, J. C., Santos, M. C. O., Siciliano, S., Echegaray, M., Vididi, F., Félix, F., Crespo, E., Sanino, G. P., Avila, I. C., Fraijia, N., & Castro, C. (2008). Skin diseases in cetaceans (SC/60/DW8). *Reports of the International Whaling Commission*.
- Wells, R. S., & Scott, M. D. (1997). Seasonal incidence of boat strikes on bottlenose dolphins near Sarasota, Florida. *Marine Mammal Science*, 13(3), 475-480. <https://doi.org/10.1111/j.1748-7692.1997.tb00654.x>
- Wilson, B., Thompson, P. M., & Hammond, P. S. (1997). Skin lesions and physical deformities in bottlenose dolphins in the Moray Firth: Population prevalence and age-sex differences. *Ambio*, 26(4), 243-247. <https://www.jstor.org/stable/4314594>
- Yang, W-C., Chang, W-L., Kwong, K-H., Yao, Y-T., & Chou, L-S. (2013). Prevalence of epidermal conditions in critically endangered Indo-Pacific humpback dolphins (*Sousa chinensis*) from the waters of Western Taiwan. *Pakistan Veterinary Journal*, 33(4), 505-509.

Humpback and Bottlenose Dolphin Skin Lesions

Table S2. Percentage agreement in the categorisation of lesion type between observers for humpback and bottlenose dolphin assessments

Trauma classification	Primary lesion category	% observer agreement	
		Humpback	Bottlenose
Nontraumatic	Annular lesion	80.0	--
	Dark lesion	60.9	71.8
	Orange spots/film	60.0	100.0
	Pale dermatitis	--	0.0
	Pale lesion	78.9	100.0
	Nodular	50.0	85.7
	Targetoid	43.2	95.0
Traumatic	Abrasions	99.8	97.5
	Anthropogenic	64.0	92.5
	Bite wounds	60.6	100.0
	Indentation	91.4	95.4
	Laceration	76.9	--
	Missing tip	88.9	98.3
	Open wound	80.0	75.0
	Unknown scarring	93.6	96.9

Table S3. Prevalence of primary skin lesion extent categories on Australian humpback and Indo-Pacific bottlenose dolphins in Moreton Bay, Queensland. Low extent equates to < 20% of the visible epidermis being covered in lesions, medium equates to 20 to 50%, and high equates to > 50%. The table shows the prevalence of lesions according to each primary lesion type. All lesions recorded on different body segments on the same individual were tallied according to extent category. For example, if an individual exhibited low extent of dark lesions on the flank and medium extent on the caudal peduncle, both were scored against the correspondent extent categories.

Trauma classification	Lesion extent: Primary lesion category	Humpback						Bottlenose					
		Low		Medium		High		Low		Medium		High	
		<i>n</i>	%	<i>n</i>	%	<i>n</i>	%	<i>n</i>	%	<i>n</i>	%	<i>n</i>	%
Nontraumatic	Annular lesion	--	--	1	1.1	1	1.1	--	--	--	--	--	--
	Dark lesion	22	24.2	--	--	--	--	41	41.0	6	6.0	--	--
	Orange spots/film	6	6.6	--	--	--	--	6	6.0	--	--	--	--
	Pale dermatitis	--	--	--	--	--	--	1	1.0	1	1.0	--	--
	Pale lesion	17	18.7	3	3.3	--	--	22	22.0	2	2.0	1	1.0
	Nodular	1	1.1	--	--	--	--	4	4.0	--	--	--	--
	Targetoid	17	18.7	--	--	--	--	25	25.0	2	2.0	1	1.0
Traumatic	Abrasions	60	65.9	36	39.6	25	27.5	84	84.0	54	54.0	19	19.0
	Anthropogenic	8	8.8	3	3.3	1	1.1	25	25.0	4	4.0	1	1.0
	Bite wounds	27	29.7	23	25.3	4	4.4	24	24.0	6	6.0	1	1.0
	Indentation	9	9.9	4	4.4	--	--	33	33.0	1	1.0	--	--
	Laceration	1	1.1	1	1.1	--	--	--	--	--	--	--	--
	Missing tip	2	2.2	2	2.2	--	--	10	10.0	7	7.0	1	1.0
	Open wound	3	3.3	1	1.1	--	--	2	2.0	--	--	--	--
	Unknown scarring	33	36.3	9	9.9	--	--	54	54.0	5	5.0	1	1.0
Total # individuals		76	83.5	54	59.3	28	28.3	94	94.0	65	65.0	23	23.0